

Henry P. Parkman, M.D., Series Editor

## Pathophysiology of Neurogastroenterological Disorders: GI Motility and Sensory Disorders



Mira M. Wouters



Gianrico Farrugia

**Gastrointestinal function is controlled by the coordinated action of several cell types. Functional coupling between extrinsic nerves, the enteric nervous system, interstitial cells of Cajal and smooth muscle cells results in normal gastrointestinal motility. Injury to any of these cell types may disrupt functional coupling and result in motility disorders. Together with its motor function, the gastrointestinal tract also has a “sensory” function. The sensory system of the gastrointestinal tract is complex and signals information about the chemical environment of the gastrointestinal tract lumen, tension in the gut wall and the condition of the tissue (e.g. inflammation). Functional coupling between mucosal cells, enteric nerves, interstitial cells of Cajal and smooth muscle cells underlies “sensation.” This review will help provide an understanding of the cell types that generate normal motility and sensation and changes that occur in common motility disorders.**

### ORGANIZATION OF THE CONTROL OF GASTROINTESTINAL MOTILITY

**T**he gastrointestinal tract carries out several diverse functions including mixing, enzymatic digestion, propulsion, absorption, secretion and excretion.

Mira M. Wouters, M.D., Enteric NeuroScience Program, Miles and Shirley Fiterman Center for Digestive Diseases; Gianrico Farrugia, M.D., Enteric NeuroScience Program, Miles and Shirley Fiterman Center for Digestive Diseases, and the Department of Physiology and Biomedical Engineering, both at Mayo Clinic College of Medicine, Rochester, MN.

These functions are controlled at several levels including the central nervous system and the peripheral nervous system including enteric nerves.

### Extrinsic Control

The gastrointestinal tract and the central nervous system (CNS) constantly exchange information. The CNS is informed of the state of the gastrointestinal tract by afferent neurons and hormones and is able to control or modulate digestive function through efferent neurons that are a component of the autonomic nervous system.

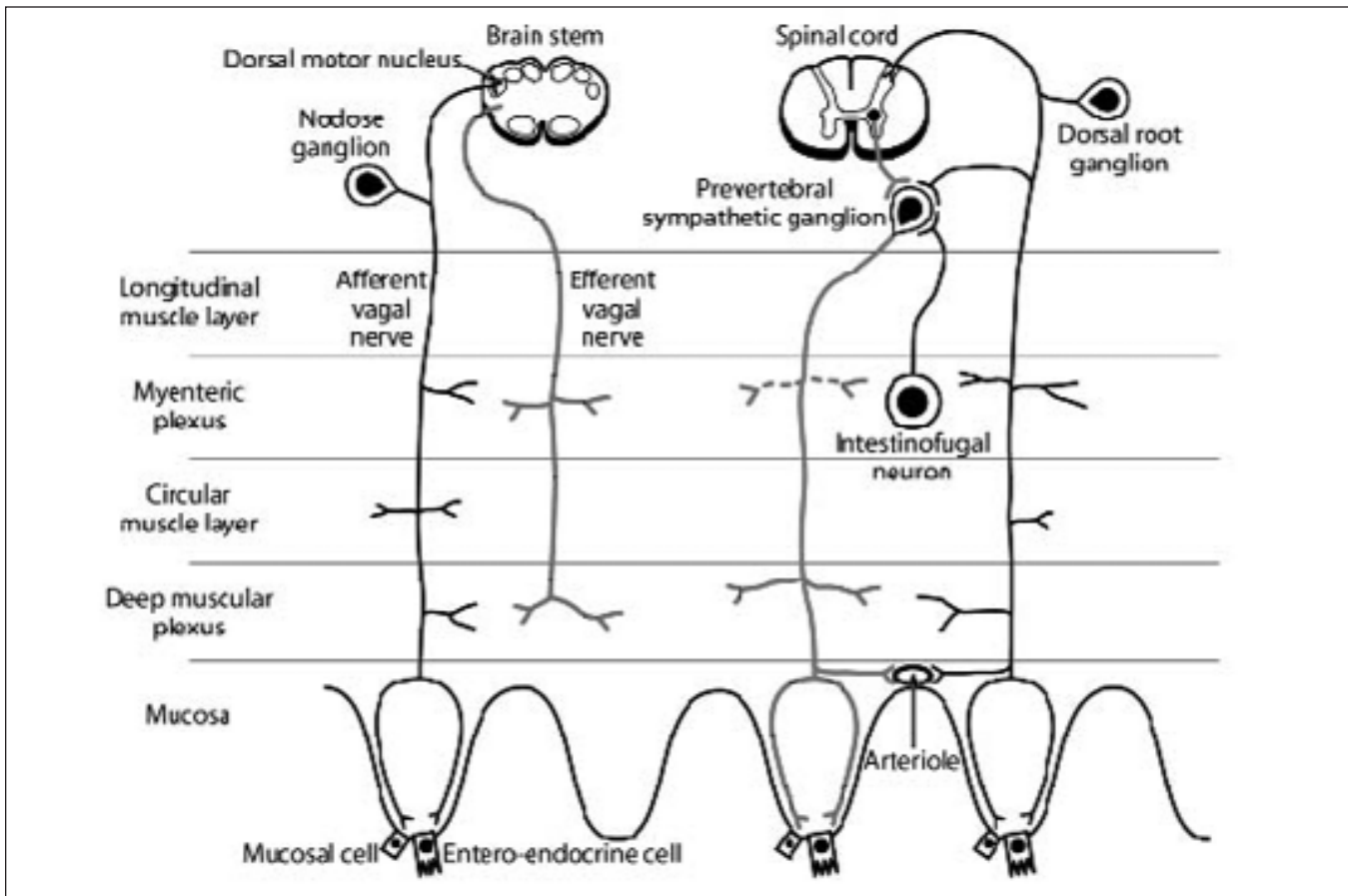


Figure 1. The gastrointestinal tract is supplied with efferent and afferent vagal and sympathetic nerves. Afferent neurons (in black) discharge in response to luminal chemicals, mechanical deformation of their terminal fields, humoral factors, cytokines and other inflammatory mediators. Efferent neurons (in grey) in both splanchnic and vagal nerve trunks terminate on myenteric and deep muscular plexus nerve cell bodies from which intrinsic motor neurons influence secretion and motility. Sympathetic efferents may also directly supply blood vessels and mucosal and entero-endocrine cells.

### Extrinsic Efferent Input

The major efferent routes regulating gut functions are the vagal motor pathways and sympathetic neurons (Figure 1). Sympathetic postganglionic neurons have cell bodies in the prevertebral (Figure 1) and paravertebral (not shown on figure) ganglia and their axons run to the enteric ganglia and also to mucosa and blood vessels (Figure 1). Cell bodies in paravertebral ganglia are mainly involved in vasoconstriction, whereas the three classes of sympathetic neurons in prevertebral ganglia are involved in vasoconstriction, motility and secretion. Norepinephrine is the primary neurotransmitter of sympathetic neurons.

Vagal preganglionic neurons have cell bodies in the brainstem that project to the gut (Figure 1) and have a variety of effects on the upper gastrointestinal tract including gastric relaxation and regulation of secretion. Nonadrenergic, noncholinergic (NANC) and cholinergic vagal efferent endings are more numerous in the esophagus and stomach than in the small intestine (1) while sparse in the colon. The colon is predominantly innervated by pelvic nerves whose cell bodies are in the sacral spinal cord. Pelvic nerves affect movement and secretion of the distal colon.

(continued on page 18)

(continued from page 16)

Unlike sympathetic axons which can directly innervate blood vessels and mucosal cells, all effects of vagal and pelvic efferent neurons are mediated via synapses on enteric neurons (Figure 1).

#### ***Extrinsic Primary Afferent Innervation of the Gastrointestinal Tract***

Extrinsic afferent pathways are responsible for sensations arising from the gut (see below) and for activating sympathetic and vagal/pelvic reflex pathways.

Extrinsic primary afferent neurons (EPANs) are subdivided in two groups: spinal primary afferent neurons and vagal primary afferent neurons (Figure 1). Vagal primary afferent neurons have cell bodies in the nodose and jugular ganglia (ganglia of the trunk and root respectively) and their axons project directly into the dorsal motor nucleus of the brainstem (Figure 1). Vagal afferent endings are more numerous in the stomach and esophagus compared to the intestine and sparse in the colon. Sacral spinal afferent pathways share many features with vagal afferents traveling with parasympathetic axons to the colon.

Spinal afferent endings have cell bodies in the dorsal root ganglia (Figure 1) and make synaptic contacts in prevertebral sympathetic ganglia and the spinal dorsal horn. Spinal afferent nerves have synapses within the enteric nervous system and are distributed throughout the gut through splanchnic nerves.

The chemical coding is different in spinal and vagal afferent neurons. Rat vagal afferent nerve endings contain calcitonin, calbindin and neurocalcin (2) while the spinal afferent nerves contain substance P and calcitonin-gene related peptide (CGRP) (3,4).

#### **Enteric Nervous System**

The enteric nervous system (ENS) generates and modulates many digestive functions without input from the central nervous system and has been described as the "little brain." The ENS consists of nerve cell bodies that are connected by their processes to form two major ganglionated plexi in the digestive tract. The submucosal (Meissner's) plexus is located between the inner layer of the circular muscle layer and the submucosa and is best developed in the small intestine and colon. The second and more prominent plexus is the

myenteric (Auerbach) plexus. It is located between the circular and longitudinal smooth muscle layers and is present throughout the gastrointestinal tract. In the small intestine an aggregation of nerve fibers without cell bodies is found between the most inner circular smooth muscle cells and the rest of the circular muscle layer and is known as the deep muscular plexus.

Most work on the identification of enteric neurons has been performed in the guinea pig but lessons learned on the organization of neurons in this species also apply to other mammals, including humans. Enteric neurons can be divided in different classes based on morphological, immunohistochemical and electrophysiological characteristics. Based on these characteristics and features, we will describe four major groups of neurons: motor neurons, intrinsic primary afferent neurons (IPANS), interneurons and intestinofugal neurons.

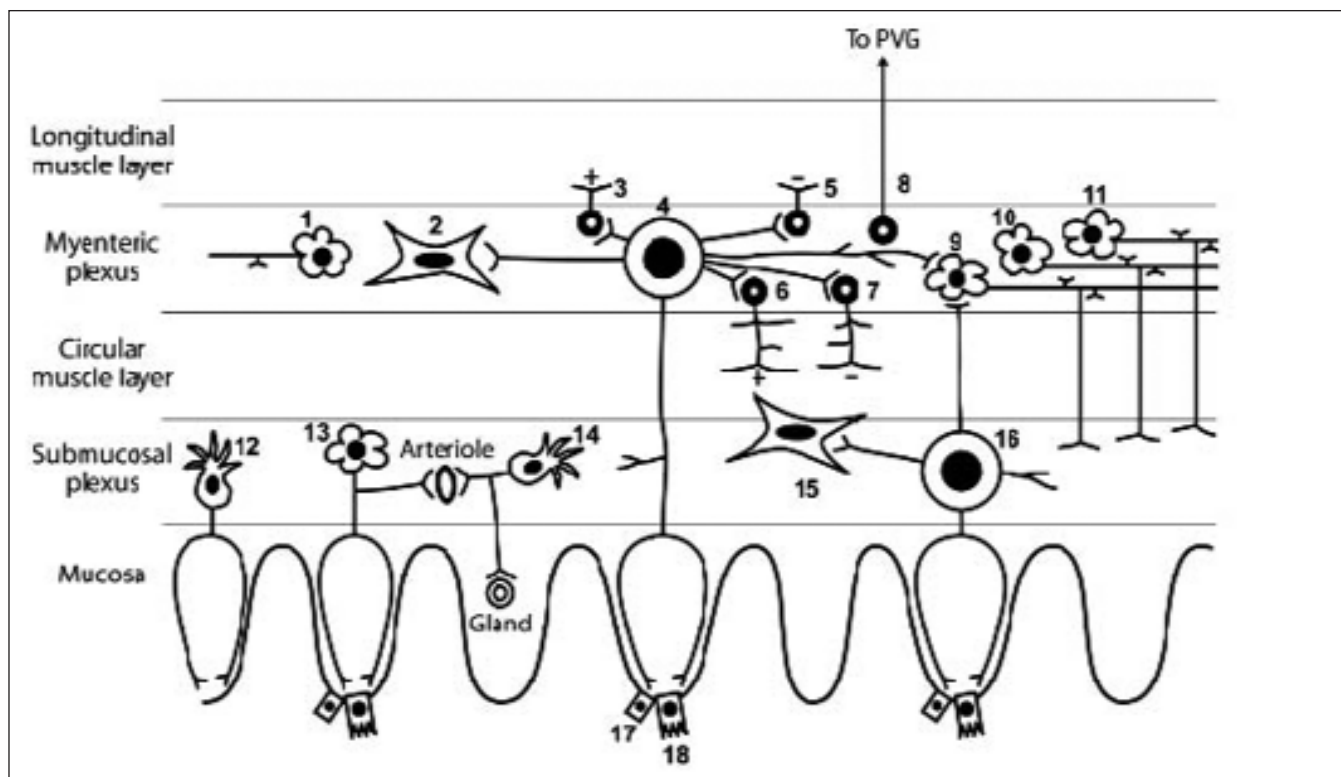
Both excitatory and inhibitory motor neurons (Figure 2) that innervate the muscularis externa are found in the myenteric plexus. The main neurotransmitters of excitatory motor neurons are acetylcholine and tachykinins (5,6) while the inhibitory motor neurons express a variety of inhibitory neurotransmitters including nitric oxide (NO), ATP, pituitary adenylyl cyclase-activating polypeptide (PACAP) and vasointestinal peptide (VIP). In the colon, motor activity is under dominant inhibitory neuronal input, slowing colonic transit for fecal contents to solidify. Motor neurons that populate the submucosal plexus, namely the secretomotor and secretomotor/vasodilator neurons, control water and electrolyte secretion and also regulate the vasculature (Figure 2).

Intrinsic primary afferent neurons (IPANS) are another set of enteric neurons. IPANS are referred to as such and not as sensory neurons as in the non-diseased gastrointestinal tract there is no sensation of normal gastrointestinal function (7). IPANS receive their information from the enterochromaffin cells and are strictly therefore not the primary cells in the afferent pathway. IPANS have extensive projections in the circumferential axis of the gut and are located in both plexi where they make contact with other IPANS, interneurons and motor neurons (Figure 2).

The third class of enteric neurons, the interneurons, has been identified in all regions of the gut. Within the myenteric plexus, chains of interneurons can run both

(continued on page 21)

(continued from page 18)



**Figure 2. Types of neurons in the small intestinal enteric nervous system.**

*Myenteric plexus neurons:* 1. ascending interneuron; 2. Myenteric plexus interstitial cell of Cajal; 3. excitatory longitudinal muscle motor neuron; 4. Myenteric intrinsic primary afferent neuron; 5. inhibitory longitudinal muscle motor neuron; 6. excitatory circular muscle motor neuron; 7. inhibitory circular muscle motor neuron; 8. intestinofugal neuron; 9. descending interneuron (local reflex); 10. descending interneuron (secretomotor reflex); 11. descending interneuron (migrating myoelectrical complex); A fourth type of interneuron may be present (8). *Submucosal plexus neurons:* 12. cholinergic secretomotor (nonvasodilator) neuron; 13. cholinergic secretomotor vasodilator neuron; 14. non-cholinergic secretomotor vasodilator neuron; 15. deep muscular plexus interstitial cell of Cajal; 16. submucosal intrinsic primary afferent neuron; 17. mucosal cell; 18. entero-endocrine cell  
Cartoon adapted from Furness JB. The enteric nervous system. 2006: Blackwell Publishing.

orally and anally. In guinea pig small intestine, at least four classes of descending interneurons and one class of ascending cholinergic interneurons are described (Figure 2) (8). The ascending and three of the types of descending cholinergic interneurons are involved in local motility reflexes while the fourth type of descending interneurons runs along the intestine and is involved in the conduction of the migrating myoelectrical complex. Each of these four types of descending interneurons, unlike the ascending interneurons, also provides innervation to submucosal ganglia indicating that interneurons connect the two plexi.

Intestinofugal neurons are neurons that have cell bodies in the myenteric plexus while the axons project

out of the gut (Figure 2) where they form synapses with post-ganglionic sympathetic neurons (9). There are two general populations of intestinofugal neurons. Primary intestinofugal neurons project without synaptic interruption to prevertebral ganglia (PVG) and can therefore be considered as a special type of interneurons (10). A second population of intestinofugal neurons receives fast synaptic input from other enteric neurons before exiting the bowel wall (9).

### Interstitial Cells of Cajal

Interstitial cells of Cajal (ICC) are a specialized mesenchymal cell type in the gastrointestinal tract that are

neither neurons nor smooth muscle cells. The distribution of ICC has been studied in different species including mouse, rat and human and appears to be fairly consistent in different species. In the body of the stomach, ICC form a dense network surrounding the myenteric plexus (ICC-MP) and they are abundantly present in the muscle layers especially in the circular layer (ICC-IM). ICC-MP are lacking in the fundus of the stomach. In the intestine, besides an extensive ICC-MP network, a subclass of ICC is present at the level of the deep muscular plexus (ICC-DMP). In small mammals, ICC-IM are generally lacking in the muscle layer of the intestine. In the colon, ICC are present at the level of the subserosa (ICC-SS), in the muscle layer (ICC-IM), at the level of the myenteric plexus (ICC-MP) and at the level of the submucosal plexus (ICC-SMP).

The best studied function of ICC is the generation of spontaneous, rhythmic electrical oscillations called slow waves (the pacemaker function of ICC). In stomach and small intestine, ICC-MP in conjunction with ICC-IM generate and propagate slow waves while slow waves appear to originate in ICC-SMP in the colon although ICC-MP also appear to generate a signal of higher frequency.

Slow waves are conducted passively to neighboring smooth muscle where they produce rhythmical membrane potential changes. As contractions only occur during the depolarization phase of the slow wave, slow waves determine the maximal frequency of the electromechanical activity of the gastrointestinal musculature. Release of neurotransmitters by motor neurons of the enteric nervous system during the depolarization phase of the slow wave alters the response of smooth muscles to the slow wave.

There are two ways in which enteric nerves can regulate gastrointestinal smooth muscle cell contractility. Subclasses of ICC such as ICC-IM and ICC-DMP are in close contact with varicose endings of enteric motor neurons (11). These ICC are involved in the conduction and amplification of neuronal signals from excitatory cholinergic and inhibitory nitrenergic motor neurons (12,13). This is referred to as the serial model of neurotransmission where both excitatory and inhibitory motor neurons innervate exclusively the interstitial cells of Cajal which transfer the signal to the muscle by electrical coupling. In the parallel model,

both ICC and smooth muscle cells receive direct neuronal inputs (14) (Figure 2). The parallel model is based on ultra structural evidence for both direct and indirect muscle innervation (15) including transmission electron microscopy which demonstrates that motor neurons make direct contact to the smooth muscle cells (16). The dominant mechanism varies according to the region of the gut and the neurotransmitter involved.

Together with the role of ICC in pacing the gastrointestinal tract and amplifying neurotransmission, ICC also release carbon monoxide (CO) (17–19), a critical hyperpolarizing factor required for the maintenance of intestinal smooth muscle cells membrane potential and its gradient (20) and act as mechanosensors (21,22).

### MOTOR PATTERNS OF THE GI TRACT

The stomach receives and mixes food; the small intestine facilitates emptying from the stomach, mixes chyme and delivers the residue to the colon where fecal contents are solidified before excretion. In order to operate properly, different gastrointestinal segments have unique motor patterns.

#### Peristalsis

Propulsive peristalsis is a distinct pattern of synchronized smooth muscle contractions and relaxation that propels food distally through the esophagus and small intestine. Peristaltic movements can be evoked by mechanical (a bolus) or chemical stimuli. During a peristaltic contraction the slow wave frequency, produced by ICC, remains unchanged. However, the number of action potentials generated by excitatory motor neurons superimposed on the slow wave is increased. Often, a second group of inhibitory motor neurons below the bolus induce relaxation to help pass the bolus. Peristalsis is controlled by the intrinsic nervous system without extrinsic neuronal input.

#### Migrating Myoelectrical Complex

The migrating myoelectrical complex (MMC) is a distinct pattern of electromechanical activity observed in gastrointestinal smooth muscle during fasting (23). Periodically, in dogs and man, at intervals of about 90 minutes, a wave of intense contractile activity begins

in the stomach and is propagated aborally through the small intestine to the ileum. During the MMC the pylorus remains open, allowing passage of larger undigested material than is normally allowed to pass through the pylorus. The MMC is thought to serve a “housekeeping” role and sweeps residual undigested material through the digestive tube. The cycle consists of 4 phases: I, a quiescent period lasting 45 to 60 minutes, II, an irregular phase of 30 minutes with random activity, III, a period of intense activity that lasts for 5 to 15 minutes in which rapid, evenly spaced contractions occur and IV, a transitional period between the burst of contractions in phase 3 and the inactivity of phase 1. The phases of the interdigestive state disappear after a meal and are replaced by an irregular contractile activity known as the fed pattern.

The MMC originates from the intrinsic nervous system and is propagated by a specialized subset of interneurons that run along the length of the gut. The extrinsic nervous system can modulate the MMC but is not required for its initiation or propagation.

### High Amplitude Propagating Contractions

Somewhat analogous to the small intestinal MMC that sweeps unabsorbed residue to the colon is another type of motility pattern that occurs in the large intestine, the high amplitude propagating contractions (HAPC). These very strong contractions occur a few times a day and are usually absent at night. They begin in various parts of the large intestine and sweep around for various distances, sometimes reaching the rectum. These contractions move the contents of the large intestine ahead of them, and they may trigger the urge to have a bowel movement. Like the MMC, HAPCs are generated by the intrinsic nervous system.

### SENSATION OF THE GUT

Normal gastrointestinal activity does not usually evoke sensation. That is, we are usually unaware of the processes that regulate gastrointestinal motility, blood flow, secretion and absorption. However regulation of these processes does require processing of chemical and physical stimuli. The neuronal cell type that is involved in transducing these stimuli to an electrical signal and

eventually an appropriate response is referred to as primary afferent neurons rather than sensory neurons because it does not usually convey sensation. During disease processes, or occasionally as part of normal physiology, we do perceive sensation from our gut and then the primary afferent neurons take on the properties of sensory neurons. Two types of primary afferent neurons are present, intrinsic primary afferent neurons (IPANs) whose cell bodies and processes do not leave the gut and extrinsic primary afferent neurons (EPANs) whose cell bodies are outside of the gut (vagal and spinal afferents). In addition to these two cell types a third cell type, whose cell body is within the gut but whose processes leave the gut, also participates in detecting gut stimuli, the intestinofugal neurons.

### Mechanosensation

Entero-endocrine cells detect mechanical stimuli at the luminal level and their stimulation results in release of paracrine mediators including serotonin but also cholecystokinin (CCK), gastrin, somatostatin and peptide YY into the lamina propria of the epithelium to activate the appropriate intrinsic and extrinsic neurons in the submucosal plexus.

Mechanosensitive sensors detecting stretch and distortion of the muscle layer are present on primary intrinsic and extrinsic afferent neurons. Stretch-sensitive IPANs respond to tension in the muscle and to direct distortion of their processes (24,25). They have stretch-sensitive ion channels that are gated by changes in membrane tension and the accompanying alterations in membrane potential lead to the propagation of action potentials. Recently, in the colon, another specialized type of intrinsic mechanosensitive neurons, most likely interneurons, has been identified (26).

Vagal mechanosensitive EPANs are activated by low-intensity mechanical stimuli (<10 mm Hg). Different classes of vagal afferents are described based on the location of the receptive field. The first class has endings in the mucosa which are activated by mucosal stroking with rapidly adapting responses and are unresponsive to distension. The second class of vagal afferents has endings in the muscle and acts as slow adapting tension receptors. They respond with a linear relationship to wall

*(continued on page 26)*

(continued from page 23)

tension within the physiological range (<10 mm Hg), signal food intake and mediate satiety and fullness (27). Another class of vagal nerves has endings that are specifically associated with ICC indicating that ICC are potentially involved in afferent neural transduction (28).

Spinal afferents, like vagal afferents, are similarly located in different layers of the gut. Importantly, they are considered to convey to the CNS the sensations of discomfort and pain. Mucosal spinal afferent nerves, like vagal mucosal afferents, have a selective response to fine tactile stimulation. Spinal afferent endings located in the muscle wall are activated by low-intensity stimuli (<10 mm Hg, low threshold mechanoreceptors) and encode signaling in the noxious, non-physiological range while a second group of spinal afferents located in the muscle wall responds to distending pressures exceeding 30 mm Hg (high threshold mechanoreceptors) and are considered as mechano-noci-receptors. They mediate acute pain in response to noxious mechanical distension and the signals originating in the gastrointestinal tract run from the prevertebral ganglia to the brain stem.

As described above, another unique subset of myenteric ganglion neurons that relay mechanosensory information from the gut represents the IFANs. IFANs carry low threshold signals that originate in the gut and communicate to the prevertebral ganglia. Unlike the spinal afferents, IFANs do not end in the brain stem (29). Mechanosensory IFANs are arranged “in parallel” with the circular muscle layer. As a result, they detect changes in volume. The frequency of synaptic input to prevertebral ganglia neurons increases in the circumference of the colon wall (29). This “in parallel” arrangement of the IFANs distinguishes them from vagal and spinal mechanosensitive afferent nerves which function as “in series” receptors (30). Their discharge frequency increases during longitudinal stretch and during active longitudinal muscle contraction.

### Chemosensation

Chemosensation is the term used to describe the capacity of afferent nerve fibers to respond to luminal stimuli such as nutrients and neurohumoral chemicals including serotonin, histamine and bradykinin.

Again, the entero-endocrine cells are the mucosal elements that detect chemical stimulation of the mucosa

and in response they release paracrine mediators which activate the appropriate intrinsic and extrinsic afferent nerves. Furthermore, immune cells like macrophages and mast cells detect immunogens and in response can release substances like histamine and serotonin that act locally in the gut wall (31). The paracrine mediators released by entero-endocrine and immune cells are detected by chemosensitive IPANs (24).

As described above, two different afferent pathways from the GI tract can conduct sensory information to the CNS. Vagal EPANs with endings in the mucosa respond to a range of intra-luminal chemical and osmotic stimuli and they generate satiety, nausea and vomiting sensations. Mucosal spinal afferent receptors have similar properties to vagal mucosal afferents in their sensitivity to luminal chemicals. However, spinal high threshold mechanoreceptors appear to be also chemosensitive, responding directly to inflammatory mediators including bradykinin, eicosanoids and free radicals. Another type of spinal chemosensitive receptors, described as silent nociceptors, is mechanically insensitive and silent at rest. They only develop activity during and after inflammation through action of inflammatory mediators and nerve growth factor (32).

### EXAMPLES OF NEUROGASTROENTEROLOGICAL DISEASES

The motility patterns and reflexes of the gastrointestinal tract are controlled by complex interactions between smooth muscle cells, the intrinsic and extrinsic nerves and ICC. It is therefore not surprising that any abnormality of smooth muscle, intrinsic or extrinsic nerves or ICC or of communication between the cell types can result in dysmotility and disease.

### Achalasia

Achalasia is an esophageal motility disorder characterized by a failure of the esophageal smooth muscle to generate effective peristalsis and by a failure of the lower esophageal sphincter to relax completely during swallowing. Several neuropathologic findings have been described including injury of inhibitory nitric oxide producing nerves, degenerative changes of the

vagus nerve and an occasional presence of cytoplasm inclusions in the dorsal motor nucleus of the vagus nerve and myenteric plexus. The initiating factor(s) and underlying mechanisms leading to these characteristic features are currently unknown (33).

### Gastroparesis

Gastroparesis refers to delayed gastric emptying in the absence of mechanical obstruction. Gastroparesis can be idiopathic or attributable to a variety of underlying disorders, most commonly diabetes and post gastric surgery. Gastroparesis can occur in isolation or be part of a generalized motility disorder such as intestinal pseudo-obstruction and diabetic gastroenteropathy. The pathophysiology of gastroparesis is varied and includes smooth muscle fibrosis (34–36), loss of enteric nerves (37), extrinsic neuropathy (38) and loss of ICC (35). Recent data suggest a significant role for loss of nNOS expression in enteric nerves and loss of organized ICC networks as dominant cellular defects in diabetic gastroparesis. It is unknown if these findings are applicable to other causes of gastroparesis.

### Chronic Intestinal Pseudo-obstruction

Chronic intestinal pseudo-obstruction (CIPO) is characterized by impaired propulsion together with symptoms and signs of bowel obstruction in the absence of any lesions occluding the gut lumen (39–41). CIPO can be secondary to a wide array of systemic conditions such as amyloid and scleroderma or be limited to a targeted defect in the intestinal tract. CIPO is further classified as myopathic when the dominant affected cell type is smooth muscle or ICC (the latter also referred to as an interstitial cell of Cajalopathy) and neuropathic when the dominant affected cell type is nerves. Loss of ICC or loss of distinct networks of ICC (42) has been reported in CIPO. In the CIPO associated with scleroderma muscle fibrosis dominates the histological picture. Recent data suggest that a subset of CIPO is due to auto antibodies directed against enteric nerves. Anti-acetylcholine receptor antibodies (43) are found in some patients with CIPO. Injection of these antibodies in animals can reproduce the disease suggesting a pathogenic role. We are also increasingly aware of the role of neuro-immune interactions in regulating gastroin-

testinal function both as a result of an unknown insult, perhaps infective, as well as a consequence of a tumor outside the gastrointestinal tract. The latter is typically due to small cell lung cancers with the immune response to the tumor also attacking enteric neurons (44) and interstitial cells of Cajal (paraneoplastic dysmotility) (45). Most patients with paraneoplastic dysmotility are ANNA-1 (anti Hu) positive which often serves as a diagnostic marker of the underlying tumor and should trigger a search for a primary tumor.

### Slow Transit Constipation

In slow transit constipation (STC), the number of HAPC seen in the colon is reduced. In patients with STC who undergo a colectomy, it appeared that the cellular defect is a decrease in the total number of nerves and interstitial cells of Cajal (46). Both enteric nerves and interstitial cells of Cajal appear to be decreased due to an increase in programmed cell death—apoptosis. The trigger for the increase in apoptosis is currently not known.

### Infantile Hypertrophic Pyloric Stenosis

Infantile hypertrophic pyloric stenosis (IHPS) is a common pediatric disease characterized by hypertrophy of the circular muscle layer of the pylorus resulting in delayed gastric emptying and projectile vomiting. In IHPS patients, inhibitory nerve fibers in the circular smooth muscle and ICC (47) are absent. These cellular defects reverse in conjunction with resolution of the disease (48).

### Hirschsprung's Disease

Constipation is the dominant presenting symptom in Hirschsprung's disease. The cardinal feature of Hirschsprung's disease is an absence of enteric nerve cell bodies in the distal part of the colon and in the rectum. The extent of the defect varies from patient to patient. The absence of enteric nerves results in the inability of the distal gut to pass meconium and later, feces. Various genetic mutations, including in the receptor tyrosine kinase RET gene (49) and in the endothelin receptor-B gene (ENDR-B) are associated with the familial Hirschsprung's disease (50). Loss of interstitial cells of Cajal has also been reported in this



disease (51,52) but other studies report a normal complement of interstitial cells of Cajal (53).

#### Irritable Bowel Syndrome

The pathophysiology of irritable bowel syndrome is unknown. Described defects include visceral hypersensitivity, central perception changes, and abnormal gastrointestinal motility and secretion due to an abnormal functioning in any of the three components of the peripheral nervous system and the central nervous system (54,55), post-infective changes affecting enteric nerves as a result of altered neuro-immune interactions and altered interactions between intestinal flora and the gut.

#### Inflammatory Bowel Disease

It is increasingly apparent that together with the characteristic inflammatory changes in ulcerative colitis and Crohn disease, there are also motility disturbances. Both changes at the level of enteric nerves and in interstitial cells of Cajal have been reported (56–59).

#### CONCLUSION

The pathophysiology of most gastrointestinal motility disorders was largely unknown until a few years ago. Since then we have made significant strides in understanding the cell types that coordinate normal motility as well as the cellular changes that underlie most gastrointestinal motility disorders. A loss of subsets of enteric nerves, in particular expression of neuronal nitric oxide synthase, a loss of interstitial cells of Cajal, and changes at the smooth muscle level are now known to be present in motility disorders such as achalasia, diabetic gastroparesis and slow transit constipation.

However, the mechanisms leading to the reduction of neurons, ICC and smooth muscle cells are still largely unknown. Whether the lack of enteric neurons, ICC or smooth muscle cells is the cause or consequence of some other underlying conditions remains to be established together with the question of which cell type was firstly affected and by what inciting factor. We are beginning to make some progress. Initial research suggests that smooth muscle—ICC interactions through the stem cell factor—c-Kit pathway are required for maintenance of ICC networks (60), as is

neuronally derived nitric oxide which is now known to increase the survival of ICC (61). Loss of nerves and ICC in motility disorders appears to be due to triggering of programmed cell death. The role these complex pathways play, as well as the role of glial cells in maintaining intact neural networks, of the immune system in regulating gastrointestinal function and of a variety of growth factors such as nerve growth factor (NGF), glial cell-line derived neurotrophic factor (GDNF) and serotonin (62) needs to be better understood in order to be able to design new therapies to halt cell loss and to repopulate the affected gut. ■

#### Reference

1. Kirchgessner AL, Gershon MD. Identification of vagal efferent fibers and putative target neurons in the enteric nervous system of the rat. *J Comparat Neurol*, 1989;285(1):38-53.
2. Dutsch M, et al. Vagal and spinal afferent innervation of the rat esophagus: a combined retrograde tracing and immunocytochemical study with special emphasis on calcium-binding proteins. *J Comparat Neurol*, 1998;398(2):289-307.
3. Gibbins IL, Furness JB, Costa M. Pathway-specific patterns of the co-existence of substance P, calcitonin gene-related peptide, cholecystokinin and dynorphin in neurons of the dorsal root ganglia of the guinea-pig. *Cell & Tissue Research*, 1987; 248(2):417-437.
4. Dockray GJ, Sharkey KA. Neurochemistry of visceral afferent neurones. *Prog Brain Research*, 1986; 67:133-148.
5. Grider JR. Tachykinins as transmitters of ascending contractile component of the peristaltic reflex. *Amer J Physiol*, 1989; 257(5 Pt 1):G709-G714.
6. Holzer P. Ascending enteric reflex: multiple neurotransmitter systems and interactions. *Amer J Physiol*, 1989;256(3 Pt 1): G540-G545.
7. Kirchgessner AL, Gershon MD. Projections of submucosal neurons to the myenteric plexus of the guinea pig intestine: in vitro tracing of microcircuits by retrograde and anterograde transport. *J Comparat Neurol*, 1988;277(4):487-498.
8. Brookes SJH. Classes of enteric nerve cells in the guinea-pig small intestine. *Anatomical Record*, 2001;262:58-70.
9. Szurszewski JH, Miller SM. Physiology of prevertebral sympathetic ganglia. *Physiology of the Gastrointestinal Tract*, Fourth Edition, L.R. Johnson, Editor. 2006, Academic Press: 603-627.
10. Brookes SJ, Costa M. Functional neuroanatomy (Chapter 1), in *Pathophysiology of the enteric nervous system. A Basis for understanding functional diseases*, R. Spiller and D. Grundy, Editors. 2004, Blackwell Publishing: 3-12.
11. Wang XY, Paterson C, Huizinga JD. Cholinergic and nitrergic innervation of ICC-DMP and ICC-IM in the human small intestine. *Neurogastroenterology & Motility*, 2003;15(5): 531-543.
12. Iino S, Ward SM, Sanders KM. Interstitial cells of Cajal are functionally innervated by excitatory motor neurones in the murine intestine. *J Physiol*, 2004; 556(2): 521-530.
13. Ward SM, et al. Interstitial cells of Cajal mediate enteric inhibitory neurotransmission in the lower esophageal and pyloric sphincters. *Gastroenterology*, 1998; 115(2): 314-329.
14. Sivarao DV, et al. Lower esophageal sphincter is achalasic in nNOS(-/-) and hypotensive in W/W-V mutant mice. *Gastroenterology*, 2001; 121(1):34-42.
15. Mitsui R, Komuro T. Direct and indirect innervation of smooth

(continued on page 34)

(continued from page 28)

- muscle cells of rat stomach, with special reference to the interstitial cells of Cajal. *Cell & Tissue Research*, 2002; 309(2):219-227.
16. Gabella G. *Morphology of smooth muscle*, in *Cellular Aspects of Smooth Muscle Function*, C.J. Kao and M.E. Carsten, Editors. 1997:1-47.
  17. Farrugia G, Szurszewski JH. Heme oxygenase, carbon monoxide, and interstitial cells of Cajal. *Microscopy Research & Technique*, 1999; 47(5):321-324.
  18. Miller SM, et al. Heme oxygenase 2 is present in interstitial cell networks of the mouse small intestine. *Gastroenterology*, 1998; 114(2): 239-244.
  19. Miller SM, et al. Haem oxygenase in enteric nervous system of human stomach and jejunum and co-localization with nitric oxide synthase. *Neurogastroenterology & Motility*, 2001;13(2):121-131.
  20. Szurszewski JH, Farrugia G. Carbon monoxide is an endogenous hyperpolarizing factor in the gastrointestinal tract. *Neurogastroenterology & Motility*, 2004; 16(1): 81-85.
  21. Strege PR, et al. Sodium current in human intestinal interstitial cells of Cajal. *Amer J Physiol – Gastrointest & Liver Physiol*, 2003; 285(6): G111-G1121.
  22. Fox EA, et al. Selective loss of vagal intramuscular mechanoreceptors in mice mutant for steel factor, the c-Kit receptor ligand. *Anatomy & Embryology*, 2002; 205(4): 325-342.
  23. Szurszewski JH. A migrating electric complex of canine small intestine. *Amer J Physiol*, 1969; 217(6):1757-1763.
  24. Kunze WA, et al. Intracellular recording from myenteric neurons of the guinea-pig ileum that respond to stretch. *J Physiol*, 1998; 506(3):827-842.
  25. Kunze WA, et al. The soma and neurites of primary afferent neurons in the guinea-pig intestine respond differentially to deformation. *J Physiology*, 2000; 526(2):375-385.
  26. Spencer NJ, Hennig GW, Smith TK. A rhythmic motor pattern activated by circumferential stretch in guinea-pig distal colon. *J Physiol*, 2002;545(2):629-648.
  27. Blackshaw LA, Gebhart GF. The pharmacology of gastrointestinal nociceptive pathways. *Current Opinion in Pharmacology*, 2002; 2(6):642-649.
  28. Fox EA, et al. C-Kit mutant mice have a selective loss of vagal intramuscular mechanoreceptors in the forestomach. *Anatomy & Embryology*, 2001; 204(1):11-26.
  29. Szurszewski JH, Ermilov LG, Miller SM. Prevertebral ganglia and intestinofugal afferent neurones. *Gut*, 2002; 51(1):i6-10.
  30. Iggo A, Leek BF. An electrophysiological study of single vagal efferent units associated with gastric movements in sheep. *J Physiol*, 1967;191(1):177-204.
  31. Stead RH, et al. Intestinal mucosal mast cells in normal and nematode-infected rat intestines are in intimate contact with peptidergic nerves. Proceedings of the National Academy of Sciences of the USA, 1987; 84(9):2975-2979.
  32. Delafoy L, et al. Interactive involvement of brain derived neurotrophic factor, nerve growth factor, and calcitonin gene related peptide in colonic hypersensitivity in the rat. *Gut*, 2006;55(7):940-945.
  33. Kraichely RE, Farrugia G. Achalasia: physiology and etiopathogenesis. *Dis Esophagus*, 2006;19(4):213-223.
  34. Moscoso GJ, Driver M, Guy RJ. A form of necrobiosis and atrophy of smooth muscle in diabetic gastric autonomic neuropathy. *Pathology, Research & Practice*, 1986;181(2): 188-194.
  35. Zarate N, et al. Severe idiopathic gastroparesis due to neuronal and interstitial cells of Cajal degeneration: pathological findings and management. *Gut*, 2003; 52(7):966-970.
  36. Ejskjaer NT, et al. Novel surgical treatment and gastric pathology in diabetic gastroparesis. *Diabetic Medicine*, 1999;16(6):488-495.
  37. Takahashi T, et al. Impaired expression of nitric oxide synthase in the gastric myenteric plexus of spontaneously diabetic rats. *Gastroenterology*, 1997;113(5):1535-1544.
  38. Lobrano A, et al. Postinfectious gastroparesis related to autonomic failure: a case report. *Neurogastroenterol Motility*, 2006;18:162-167.
  39. Connor FL, Di Lorenzo C. Chronic intestinal pseudo-obstruction: assessment and management. *Gastroenterology*, 2006;130(2): S29-S36.
  40. Di Lorenzo C. Pseudo-obstruction: current approaches. *Gastroenterology*, 1999;116(4): 980-987.
  41. De Giorgio R, et al. Advances in our understanding of the pathology of chronic intestinal pseudo-obstruction. *Gut*, 2004;53(11): 1549-1552.
  42. Feldstein AE, et al. Chronic intestinal pseudoobstruction associated with altered interstitial cells of Cajal networks. *J Ped Gastroenterol Nutr*, 2003; 36(4):492-497.
  43. Vermino S, et al. Autoantibodies to Ganglionic Acetylcholine Receptors in Autoimmune Autonomic Neuropathies. *NEJM*, 2000;343(12):847-855.
  44. Lennon VA, et al. Enteric neuronal autoantibodies in pseudoobstruction with small-cell lung carcinoma. *Gastroenterology*, 1991;100(1):137-142.
  45. Pardi DS, et al. Paraneoplastic dysmotility: Loss of interstitial cells of Cajal. *Amer J Gastroenterol*, 2002; 97(7):1828-1833.
  46. He CL, et al. Decreased interstitial cell of cajal volume in patients with slow-transit constipation. *Gastroenterology*, 2000; 118(1): 14-21.
  47. Vanderwinden JM, et al. Study of the interstitial cells of Cajal in infantile hypertrophic pyloric stenosis. *Gastroenterology*, 1996; 111(2): 279-288.
  48. Piotrowska AP, Solari V, Puri P. Distribution of heme oxygenase-2 in nerves and interstitial cells of Cajal in the normal pylorus and in infantile hypertrophic pyloric stenosis. *Arch Pathol Laborat Med*, 2003;127(9):1182-1186.
  49. Luo Y, et al. Close Linkage with the RET Protooncogene and Boundaries of Deletion Mutations in Autosomal Dominant Hirschsprung Disease. *Human Molecular Genetics*, 1993;11: 1803-1808.
  50. Robertson K, Mason I, Hall S. Hirschsprung's disease: genetic mutations in mice and men. *Gut*, 1997;41(4):436-441.
  51. Rolle U, et al. Altered distribution of interstitial cells of Cajal in Hirschsprung disease. *Arch Pathol Laborat Med*, 2002;126(8): 928-933.
  52. Vanderwinden JM, et al. Interstitial cells of Cajal in human colon and in Hirschsprung's disease. *Gastroenterology*, 1996; 111(4): 901-910.
  53. Newman CJ, et al. Interstitial cells of Cajal are normally distributed in both ganglionated and aganglionic bowel in Hirschsprung's disease. *Pediatr Surg Int*, 2003;19:662-668.
  54. Chang L. Brain responses to visceral and somatic stimuli in irritable bowel syndrome: a central nervous system disorder? *Gastroenterol Clin N Amer*, 2005;34(2): 271-279.
  55. Posserud I, Ersryd A, Simren M. Functional findings in irritable bowel syndrome. *W J Gastroenterol*, 2006;12(18): 2830-2838.
  56. Der T, et al. Interstitial cells of Cajal and inflammation-induced motor dysfunction in the mouse small intestine. *Gastroenterology*, 2000;119(6):1590-1599.
  57. Faussone-Pellegrini MS, et al. Alterations of neurokinin receptors and interstitial cells of Cajal during and after jejunal inflammation induced by *Nippostrongylus brasiliensis* in the rat. *Neurogastroenterology & Motility*, 2002;14(1): 83-95.
  58. Keranen U, et al. Changes in substance P-immunoreactive innervation of human colon associated with ulcerative colitis. *Dig Dis Sci*, 1995;40(10):2250-2258.
  59. Wang XY, et al. Pathology of interstitial cells of Cajal in relation to inflammation revealed by ultrastructure but not immunohistochemistry. *Amer J Pathol*, 2002;160(4): 1529-1540.
  60. Horvath VJ, et al. Reduced Stem Cell Factor Links Smooth Myopathy and Loss of Interstitial Cells of Cajal in Murine Diabetic Gastroparesis. *Gastroenterology*, 2006; 130(3):759-770.
  61. Choi KM, et al. Loss of neuronal nitric oxide synthase results in altered volume and distribution of interstitial cells of Cajal in mouse stomach (Abstract). *Neurogastroenterology & Motility*, 2005; 17(4):612.
  62. Wouters MM, et al. Proliferation of the interstitial cells of Cajal is induced by serotonin through 5-HT2B receptors (abstract). *Neurogastroenterology & Motility*, 2006;18:759.
  63. Furness JB. *The enteric nervous system*. 2006: Blackwell Publishing.